

## Letter to the Editor

## The importance of evaluating patients with MINOCA (myocardial infarction with non-obstructive coronary arteries)



Abdul Rauf Sheikh<sup>a,b</sup>, Samuel Sidharta<sup>a,c</sup>, Matthew I. Worthley<sup>a,c</sup>, Richard Yeend<sup>c</sup>, David P. Di Fiore<sup>a,b</sup>, John F. Beltrame<sup>a,b,\*</sup>

<sup>a</sup> Discipline of Medicine, University of Adelaide, Adelaide, South Australia 5011, Australia

<sup>b</sup> Cardiology Unit, The Queen Elizabeth Hospital, Central Adelaide Local Health Network, 28 Woodville Road, Woodville South, South Australia 5011, Australia

<sup>c</sup> Cardiology Unit, Royal Adelaide Hospital, Central Adelaide Local Health Network, North Terrace, Adelaide, SA 5000, Australia

## ARTICLE INFO

## Article history:

Received 6 July 2015

Accepted 7 July 2015

Available online 11 July 2015

## Keywords:

MINOCA

Myocardial bridge

Vasospastic angina

Microvascular dysfunction

Coronary artery disease

Hyperemic microvascular resistance

Acute myocardial infarction (AMI) is associated with obstructive coronary artery disease (i.e.  $\geq 50\%$  stenosis) in over 90% of patients undergoing angiography [1]. These patients have well-established therapeutic guidelines, which often involve coronary revascularization. However those patients with AMI with non-obstructive coronary arteries (MINOCA) present a therapeutic predicament since coronary revascularization is not appropriate and the etiology of the infarct is not immediately apparent, yet there are no therapeutic guidelines relating to the management of these patients [2]. However, identifying the etiology of MINOCA is key in the management of these patients as illustrated by this case history of a 44-year old male with recurrent chest pain, who experienced two non-ST elevation myocardial infarctions (NSTEMIs) despite the absence of obstructive coronary artery disease (CAD).

In December 2012, he first experienced significant chest pain. His coronary risk factors included being an ex-smoker, hypertension and a family history of premature coronary artery disease. On admission to hospital, he was noted to have non-specific ST depression but serial troponins excluded AMI. A coronary CT angiogram found no evidence of obstructive CAD, so he was diagnosed with unstable angina and man-

aged with calcium channel blocker (CCB). Over the ensuing 12 months, he continued to experience recurrent chest pain prompting investigations for non-cardiac causes. Pulmonary embolism, gastro-esophageal reflux and esophageal spasm, were all excluded with pertinent investigations.

In November 2013, he presented to the emergency department with a prolonged chest pain with subsequent ECGs and troponins confirming an inferior NSTEMI. Invasive coronary angiography was undertaken and confirmed the diagnosis of MINOCA. It also demonstrated the presence of a myocardial bridge (MB) producing dynamic compression of the mid-left anterior descending (LAD) artery. Cardiac MRI confirmed a small inferobasal sub-endocardial infarct. He was discharged on incremental CCB and nitrates but continued to experience recurrent episodes of angina.

One month later, he re-presented with NSTEMI. Invasive angiography was repeated and demonstrated similar findings to the previous study. Following discharge he continued to experience recurrent angina unresponsive to the combination of beta-blocker, CCB and nitrates. He was therefore referred for invasive coronary hemodynamic testing.

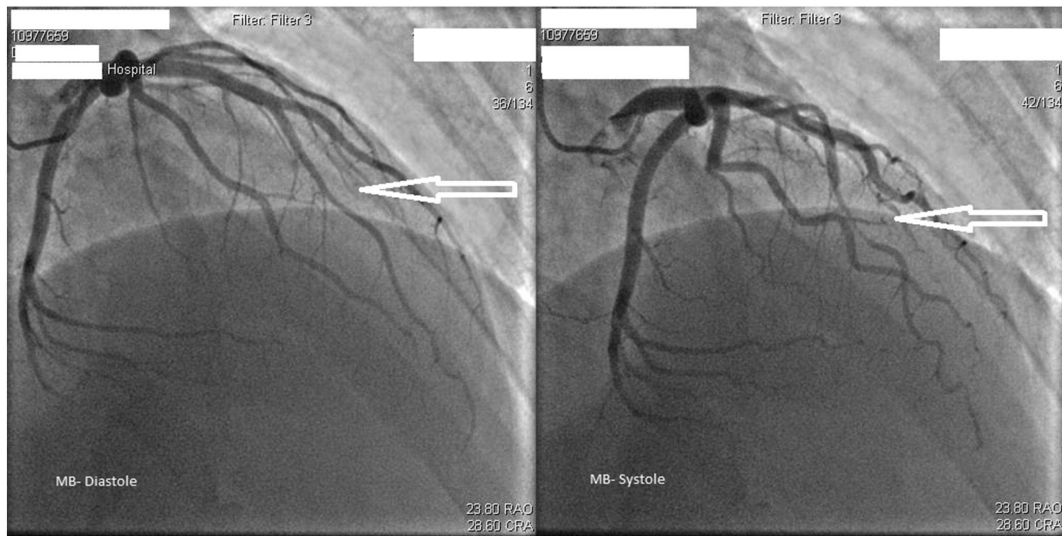
The objective of the testing was to assess: (i) the hemodynamic significance of the MB, (ii) the presence of coronary microvascular dysfunction, and (iii) the predilection to large vessel coronary spasm. Upon cessation of vasoactive agents for 36 h, a 5 F right radial artery approach was used with diagnostic images again confirming the absence of obstructive CAD. A 5 F temporary pacing electrode (required for provocative spasm testing) was inserted into the right ventricle via a cubital vein approach and the threshold set to 50 bpm.

The mid-LAD MB was again evident and visually appeared to be occlusive (Fig. 1). An intracoronary combined pressure and flow velocity wire 'Combwire' (Volcano Corporation, San Diego, CA, USA) was advanced to the LAD. Coronary Doppler blood flow velocity was continuously measured with resting recordings specifically made proximal and distal to the MB. The proximal recording showed the characteristic 'fingertip' phenomenon associated with a MB (video-1), which disappeared once the wire tip was advanced beyond the MB.

In addition to the qualitative assessment of the MB, quantitative measures were undertaken utilizing derived velocity and pressure measurements at maximal hyperemia. Accordingly, using intravenous adenosine at 170  $\mu\text{g}/\text{kg}/\text{min}$ , coronary flow reserve (CFR), fractional flow reserve (FFR) and hyperemic microvascular resistance (HMR) were

\* Corresponding author at: The Queen Elizabeth Hospital, Discipline of Medicine, University of Adelaide, 28 Woodville Road, Woodville South, SA 5011, Australia.

E-mail address: [john.beltrame@adelaide.edu.au](mailto:john.beltrame@adelaide.edu.au) (J.F. Beltrame).



**Fig. 1.** Mid-LAD myocardial bridge segment during diastole and systole; showing significant stenosis during systolic phase.

assessed. FFR across the MB found no evidence of hemodynamically significant obstruction (FFR = 0.86). Further assessment of the distal microvasculature found no evidence of coronary microvascular dysfunction (CFR = 3.6, HMR = 1.2). Similarly, assessment of the right coronary artery (RCA), found no evidence of coronary microvascular dysfunction (CFR = 4.8, HMR = 1.4).

Provocative spasm testing was then initiated utilizing the conventional acetylcholine (ACh) testing protocol [3]. Following baseline angiographic cine images (Fig. 2a), 25 µg of ACh was injected into the RCA as a rapid bolus over 20 s. This precipitated the patient's typical angina. Angiography demonstrated total occlusion of the proximal RCA (Fig. 2b), confirming the diagnosis of vasospastic angina. The spasm was immediately treated with 200 µg of intracoronary glyceryltrinitrate, resulting in the resolution of the chest pain. Subsequent angiographic images showed a large caliber RCA with TIMI III flow (Fig. 2c).

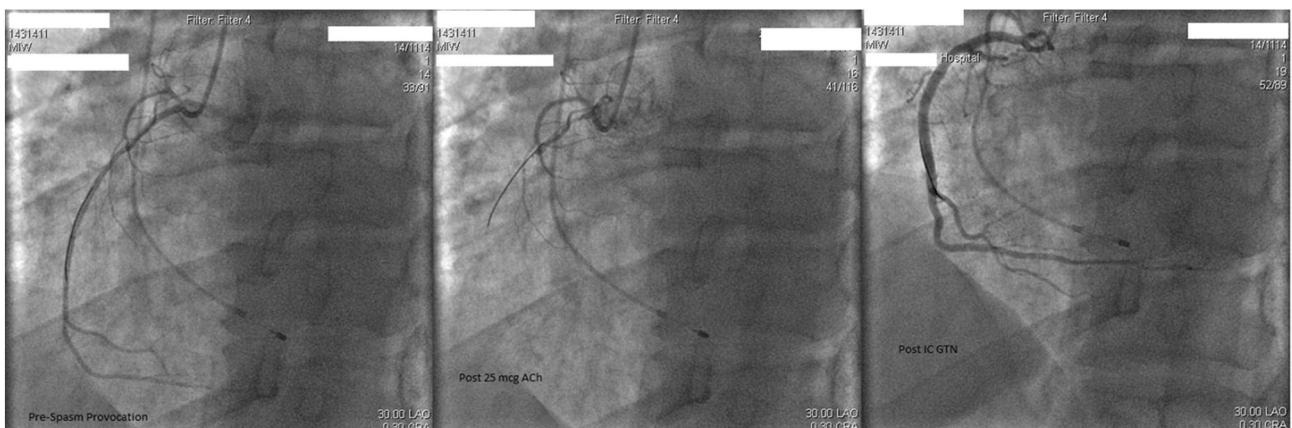
Following this comprehensive hemodynamic investigation, the patient's beta-blocker was ceased and high dosage CCB utilized with regular nitrates. Despite this extensive anti-vasospastic therapy, the patient still continues to experience daily episodes of chest pain at 6 months following the procedure albeit less frequently and less severe than previously.

This case exemplifies the complexity and importance of evaluating patients with MINOCA. This man with cardiovascular risk factors and

refractory angina, has experienced two NSTEMIs yet has no angiographic evidence of obstructive CAD. Moreover extensive investigations have been undertaken that reveal (a) no gastrointestinal cause for his chest pain, (b) a mid-LAD MB with dynamic obstruction but no fixed obstructive lesion, (c) normal coronary microvascular vasodilatory function, and (d) inducible occlusive RCA spasm, the likely cause of his angina.

MINOCA has a 6% prevalence of all AMI presentations and there is no distinguishing clinical presentation features compared with patients with obstructive CAD. These patients have guarded 12-month prognosis, although better than obstructive CAD patients [4]. Identifying the underlying abnormality is especially important for potentially life threatening conditions that are amenable to treatment, such as coronary artery spasm. Coronary spasm is associated with myocardial infarction, arrhythmias and sudden death [5,6], yet is responsive to CCB and nitrates [7].

A myocardial bridge is a congenital anatomical coronary variant characterized by a band of myocardial fibers overlaying a 'tunneled' epicardial coronary artery segment [8], which may potentially obstruct coronary blood flow thereby precipitating myocardial ischemia and symptomatic angina. Whether these congenital anomalies are responsible for the patient's recently developed symptoms requires close evaluation since surgical intervention may be warranted in severe cases. Accordingly, comprehensive physiological assessment is important to delineate the true hemodynamic significance of MB [9].



**Fig. 2.** (a, b & c) Spasm provocation testing of RCA: (a) Pre-spasm provocation, (b) post-25 µg intracoronary ACh & (c) post-intracoronary glyceryltrinitrate.

In conclusion recurrent symptoms with angiographically 'normal' coronary arteries, especially in the context of MINOCA, should lead to hemodynamic and provocation testing to further define the cause and potential treatment of a patient's symptoms [10]. Incidental myocardial bridging is often attributed as a cause of patients' symptoms yet clearly other undiagnosed causes such as coronary spasm may be responsible.

Supplementary data to this article can be found online at <http://dx.doi.org/10.1016/j.ijcard.2015.07.035>.

### Conflict of interest

The authors report no relationships that could be construed as a conflict of interest and informed consent was obtained from patient before writing up this case report.

### References

- [1] M.A. DeWood, J. Spores, R. Notske, et al., Prevalence of total coronary occlusion during the early hours of transmural myocardial infarction, *N. Engl. J. Med.* 303 (1980) 897–902.
- [2] J.F. Beltrame, Assessing patients with myocardial infarction and nonobstructed coronary arteries (MINOCA), *J. Intern. Med.* 273 (2013) 182–185.
- [3] Guidelines for diagnosis and treatment of patients with vasospastic angina (Coronary Spastic Angina) (JCS 2013), *Circ. J.* 78 (2014) 2779–2801.
- [4] S. Pasupathy, T. Air, R.P. Dreyer, R. Tavella, J.F. Beltrame, Systematic review of patients presenting with suspected myocardial infarction and nonobstructive coronary arteries, *Circulation* 131 (2015) 861–870.
- [5] R.N. MacAlpin, Cardiac arrest and sudden unexpected death in variant angina: complications of coronary spasm that can occur in the absence of severe organic coronary stenosis, *Am. Heart J.* 125 (1993) 1011–1017.
- [6] C.H. Wang, L.T. Kuo, M.J. Hung, W.J. Cherng, Coronary vasospasm as a possible cause of elevated cardiac troponin I in patients with acute coronary syndrome and insignificant coronary artery disease, *Am. Heart J.* 144 (2002) 275–281.
- [7] H. Shimokawa, 2014 Williams Harvey Lecture: importance of coronary vasomotion abnormalities – from bench to bedside, *Eur. Heart J.* 35 (2014) 3180–3193.
- [8] Y. Ishikawa, Y. Kawawa, E. Kohda, K. Shimada, T. Ishii, Significance of the anatomical properties of a myocardial bridge in coronary heart disease, *Circ. J.* 75 (2011) 1559–1566.
- [9] S. Lin, J.A. Tremmel, R. Yamada, et al., A novel stress echocardiography pattern for myocardial bridge with invasive structural and hemodynamic correlation, *J. Am. Heart Assoc.* 2 (2013) e000097.
- [10] B.K. Lee, H.S. Lim, W.F. Fearon, et al., Invasive evaluation of patients with angina in the absence of obstructive coronary artery disease, *Circulation* 131 (2015) 1054–1060.